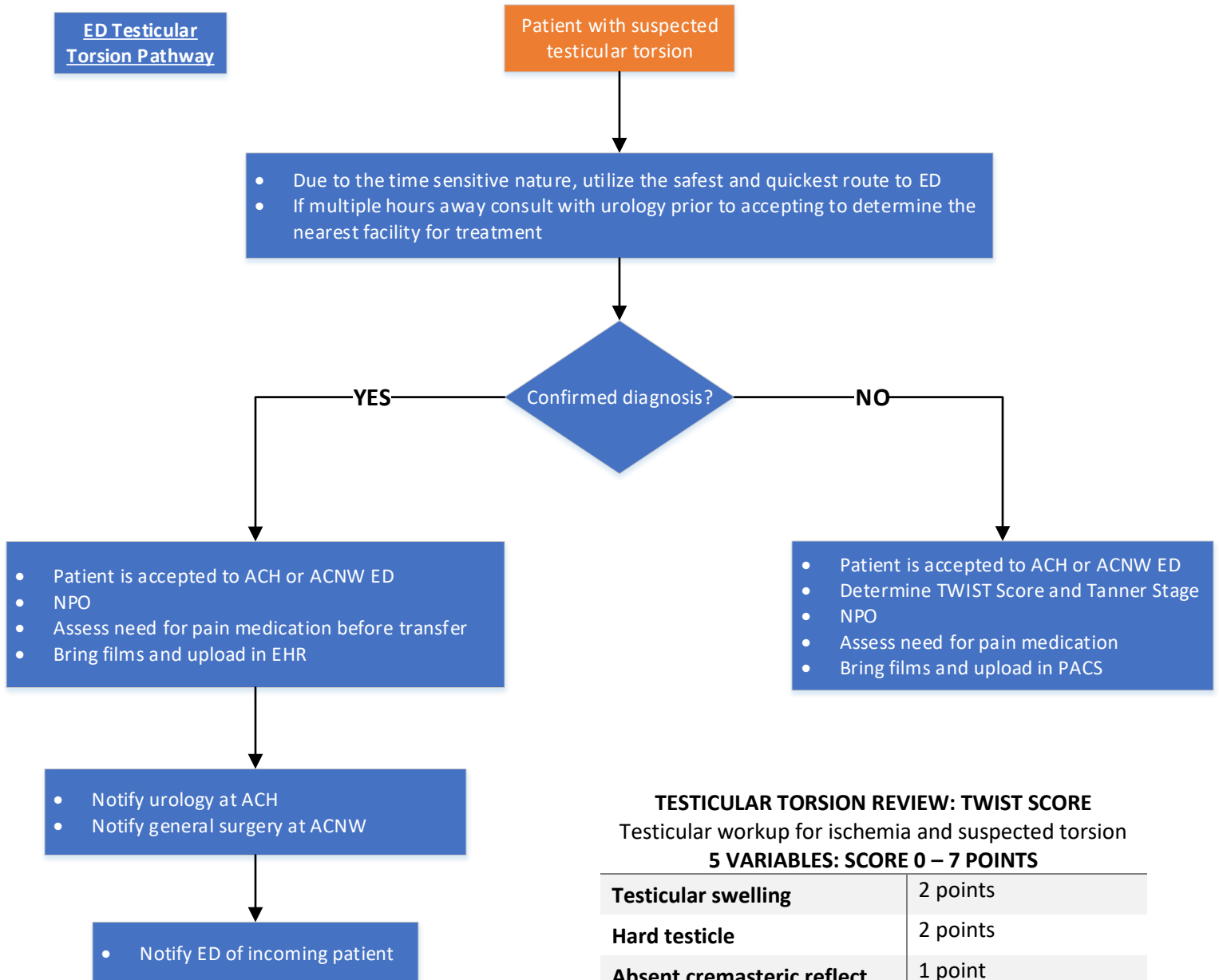


# Testicular Torsion Operations Center

Disclaimer: This clinical pathway is provided as a general guideline for use by Licensed Provider's (LPs) in planning care and treatment of patients. It is not intended to be and does not establish a standard of care. Each patient's care is individualized according to specific needs.



### TESTICULAR TORSION REVIEW: TWIST SCORE

Testicular workup for ischemia and suspected torsion  
5 VARIABLES: SCORE 0 – 7 POINTS

|                            |              |
|----------------------------|--------------|
| Testicular swelling        | 2 points     |
| Hard testicle              | 2 points     |
| Absent cremasteric reflect | 1 point      |
| Nausea/vomiting            | 1 point      |
| High-riding testis         | 1 point      |
| <b>Low Risk</b>            | 0 points     |
| <b>Intermediate Risk</b>   | 1 – 5 points |
| <b>High Risk</b>           | 6 – 7 points |

| *TANNER STAGE | PUBIC HAIR  | GENITALS  |
|---------------|---|---|
| I             | <ul style="list-style-type: none"> <li>No public hair at all</li> <li>Typically ≤ 10 years old</li> </ul>   | <ul style="list-style-type: none"> <li>Prepubescent (testicular volume &lt; 1.5 mL; small penis of ≤ 3cm)</li> <li>Typically ≤ 9 years old</li> </ul>   |
| II            | <ul style="list-style-type: none"> <li>Small amount of long, downy hair with slight pigmentation at the base of the penis and scrotum</li> <li>Typically 10 – 11.5 years old</li> </ul> | <ul style="list-style-type: none"> <li>Testicular volume 1.6 – 6mL; skin on scrotum thins, reddens and enlarges; penis length ≤ 3cm</li> <li>Typically 9 – 11 years old</li> </ul>                              |
| III           | <ul style="list-style-type: none"> <li>Hair becomes more course and curly and begins to extend laterally</li> <li>Typically 11.5 – 13 years old</li> </ul>                              | <ul style="list-style-type: none"> <li>Testicular volume 6 – 12mL; scrotum enlarges further; penis begins to lengthen to about 6cm</li> <li>Typically 11 – 12.5 years old</li> </ul>                            |
| IV            | <ul style="list-style-type: none"> <li>Adult-like hair quality, extending across pubis but sparing medial thighs</li> <li>Typically 13 – 15 years old</li> </ul>                        | <ul style="list-style-type: none"> <li>Testicular volume 12 – 20mL; scrotum enlarges further and darkens; penis increases in length to 10cm and circumference</li> <li>Typically 12.5 – 14 years old</li> </ul> |
| V             | <ul style="list-style-type: none"> <li>Hair extends to medial surface of thighs</li> <li>Typically ≥ 15 years old</li> </ul>  | <ul style="list-style-type: none"> <li>Testicular volume &gt; 20mL; adult scrotum and penis of 15cm in length</li> <li>Typically ≥ 14 years old</li> </ul>  |

# Testicular Torsion Emergency Department

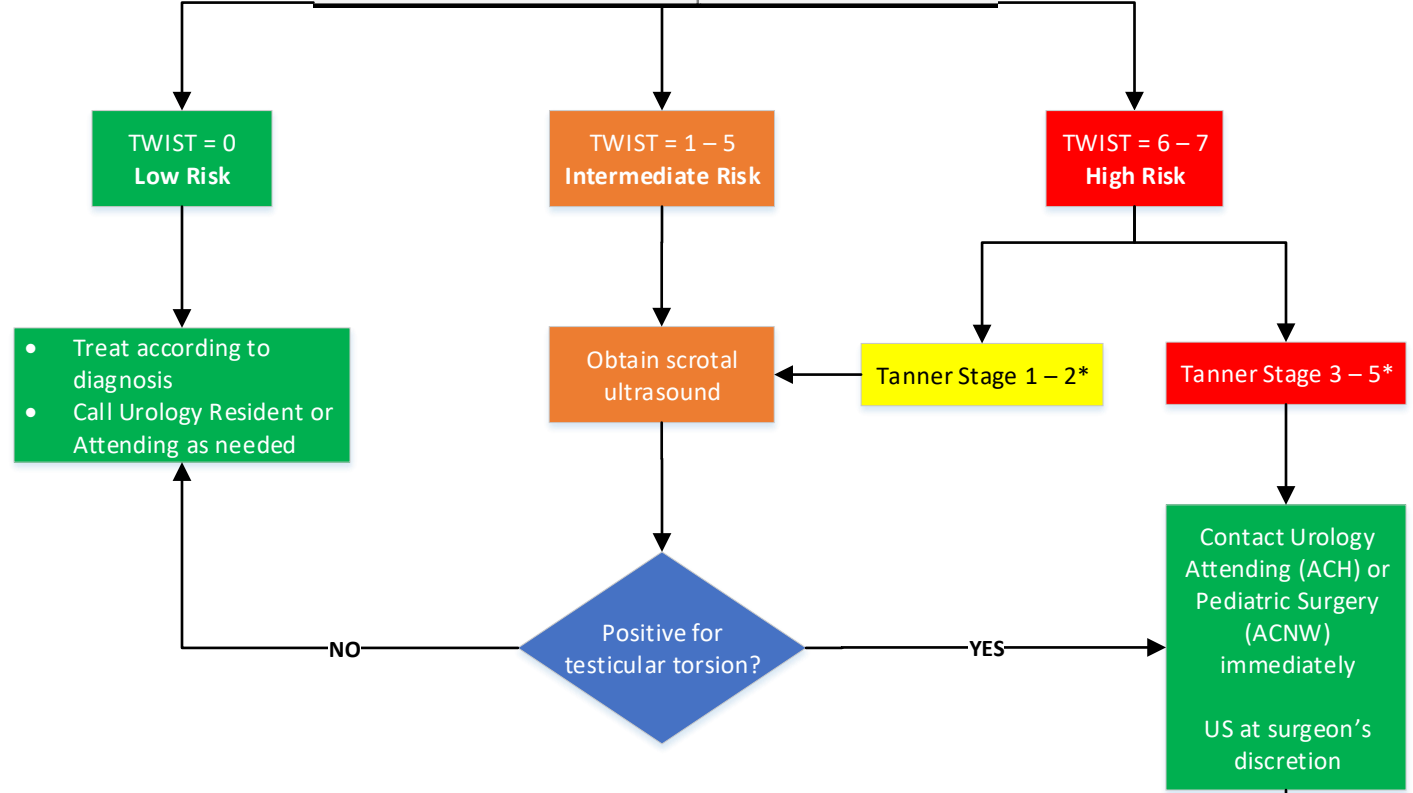
- Exclusion Criteria**
- Pain > 12 hours
  - Pain with trauma
  - Antecedent mass present

Patient presents with scrotal pain < 12 hours

- ED MD obtain H&P (note the time of onset and duration of pain)
- Place patient on cardiac monitor
- Determine TWIST Score and Tanner Stage and document in patient's chart

**TESTICULAR TORSION REVIEW: TWIST SCORE**  
Testicular workup for ischemia and suspected torsion  
**5 VARIABLES: SCORE 0 – 7 POINTS**

|                           |          |
|---------------------------|----------|
| Testicular swelling       | 2 points |
| Hard testicle             | 2 points |
| Absent cremasteric reflex | 1 point  |
| Nausea/vomiting           | 1 point  |
| High-riding testis        | 1 point  |



| *TANNER STAGE | PUBIC HAIR  | GENITALS  |
|---------------|---|---|
| I             | <ul style="list-style-type: none"> <li>• No public hair at all</li> <li>• Typically ≤ 10 years old</li> </ul>   | <ul style="list-style-type: none"> <li>• Prepubescent (testicular volume &lt; 1.5 mL; small penis of ≤ 3cm)</li> <li>• Typically ≤ 9 years old</li> </ul>   |
| II            | <ul style="list-style-type: none"> <li>• Small amount of long, downy hair with slight pigmentation at the base of the penis and scrotum</li> <li>• Typically 10 – 11.5 years old</li> </ul> | <ul style="list-style-type: none"> <li>• Testicular volume 1.6 – 6mL; skin on scrotum thins, reddens and enlarges; penis length ≤ 3cm</li> <li>• Typically 9 – 11 years old</li> </ul>                              |
| III           | <ul style="list-style-type: none"> <li>• Hair becomes more course and curly and begins to extend laterally</li> <li>• Typically 11.5 – 13 years old</li> </ul>                              | <ul style="list-style-type: none"> <li>• Testicular volume 6 – 12mL; scrotum enlarges further; penis begins to lengthen to about 6cm</li> <li>• Typically 11 – 12.5 years old</li> </ul>                            |
| IV            | <ul style="list-style-type: none"> <li>• Adult-like hair quality, extending across pubis but sparing medial thighs</li> <li>• Typically 13 – 15 years old</li> </ul>                        | <ul style="list-style-type: none"> <li>• Testicular volume 12 – 20mL; scrotum enlarges further and darkens; penis increases in length to 10cm and circumference</li> <li>• Typically 12.5 – 14 years old</li> </ul> |
| V             | <ul style="list-style-type: none"> <li>• Hair extends to medial surface of thighs</li> <li>• Typically ≥ 15 years old</li> </ul>  | <ul style="list-style-type: none"> <li>• Testicular volume &gt; 20mL; adult scrotum and penis of 15cm in length</li> <li>• Typically ≥ 14 years old</li> </ul>  |

Urology will contact OR to schedule emergency surgery

Surgery to treat testicular torsion

# Metrics

1. Maintain the average time from registration to OR start time to 3 - 3.5 hours

# Contributing Members

Ashay Patel, MD – Urology  
Melvin Dassigner, MD – Surgery  
Sabina Siddiqui, MD – Surgery  
Amber Morse, MD – Emergency Medicine  
Melissa Magill, MD – Emergency Medicine & Hospitalist  
Beth Storm, MD – Emergency Medicine  
Trisha Ridgell - Surgery Program Manager  
Shelly Keller, RN – Operations Center  
Sara Sanders, MD – Operations Center  
Emily Rader, RN – Clinical Effectiveness and Outcomes  
Sophia Blythe – Clinical Effectiveness and Outcomes